

## Case Report

# Trioichidism in an Adult

Dolly Bilonda-kolela<sup>1\*</sup>, Christelle Tenke<sup>1</sup>, Michel Lelo Tshikwela<sup>2</sup> & Bertin Njinou-Ngninkeu<sup>1</sup>

<sup>1</sup> Urological Medico-Surgery Centre of Douala, Douala, Cameroon

<sup>2</sup> Department of Radiology, Kinshasa University School of Medicine and Hospital, Kinshasa, Democratic Republic of the Congo

\* Dolly Bilonda-kolela, Urological Medico-Surgery Centre of Douala, Douala, Cameroon

Received: December 5, 2017      Accepted: December 17, 2017      Online Published: March 29, 2018

doi:10.22158/rhs.v3n2p25

URL: <http://dx.doi.org/10.22158/rhs.v3n2p25>

### **Abstract**

*We report a case of a rare congenital abnormality of testis number in an adult with palpable scrotal lump. Ultrasound exploration was performed and supernumerary, normal sized indurated testis on the left, without spermatic chord or ductus deferens, a typed I according to Leung classification was found intraoperatively. An interesting case to share with medical doctors.*

### **1. Background**

Polyorchidism, a rare congenital abnormality is characterized by the presence of one or more supernumerary testes in an individual. The first description of this anomaly was done by Ashfield in 1880 during an autopsy (Ashfield et al., 1880) and triorchidism is the clinical manifestation mostly encountered (Bahloul et al., 2011). The prognosis of the anomaly is determined by the risk of malignancy, its magnitude, degeneration, infertility and testicular torsion (Sarr et al., 2015). We report a case of a 54-year-old African man, who complained about a scrotal lump. This case report emphasizes and highlights the educational aspect of the case for residents and experience sharing for clinicians.

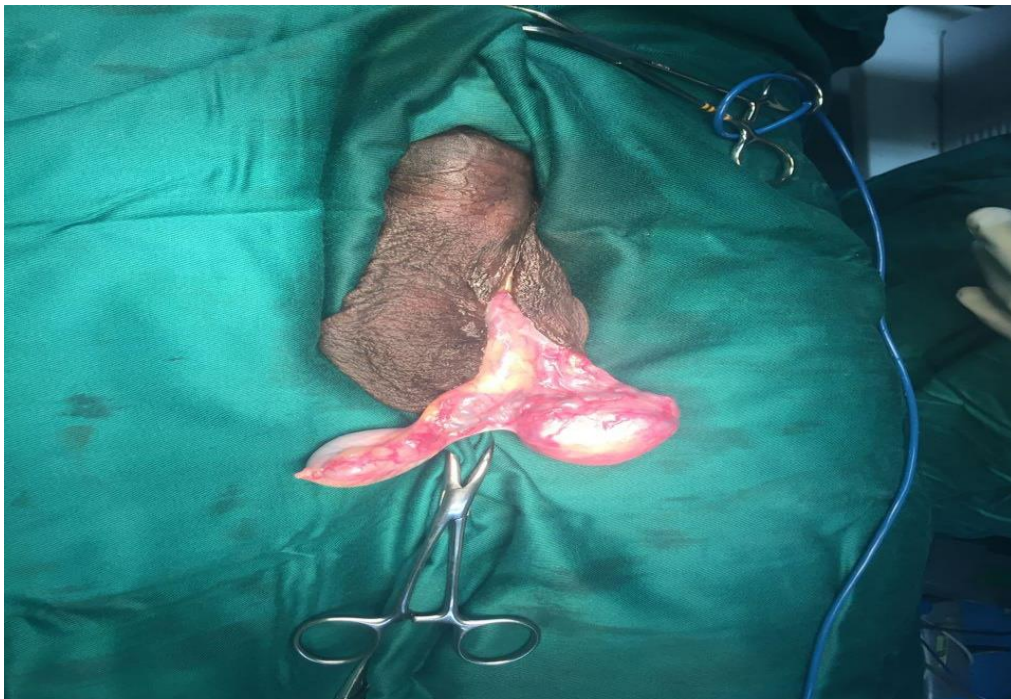### **2. Case Report**

A 54-year-old African man, married and father of four children presented to the outpatient clinic with several years history of palpable scrotal lump in both side associated with some discomfort. He highlighted that the right one would have increased in volume, while the left mass remained unchanged. Scrotal examination revealed on the left a regular round-shaped mass with a hard consistency, un-painful, mobile and located next to the normal testis, which was normal in size. Palpation of the right scrotum presented a soft mass attached to the epididymis, sensitive and transilluminable.

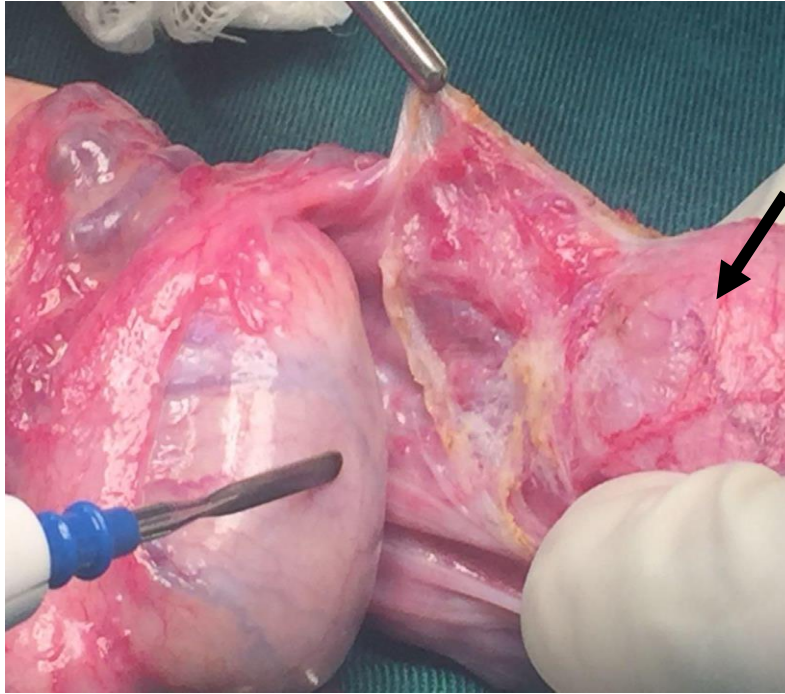
The diagnosis of left scrotal tumor and right epididymal cyst were evoked. To confirm the diagnosis,

scrotal ultrasonography was performed as first-line and sole tool of diagnostic. The left mass palpated in the left scrotum was identified with the same echogenicity as both normal testes and approximately the same volume. Contrariwise, right scrotum ultrasound showed an encapsulated fluid arising from the epididymis.

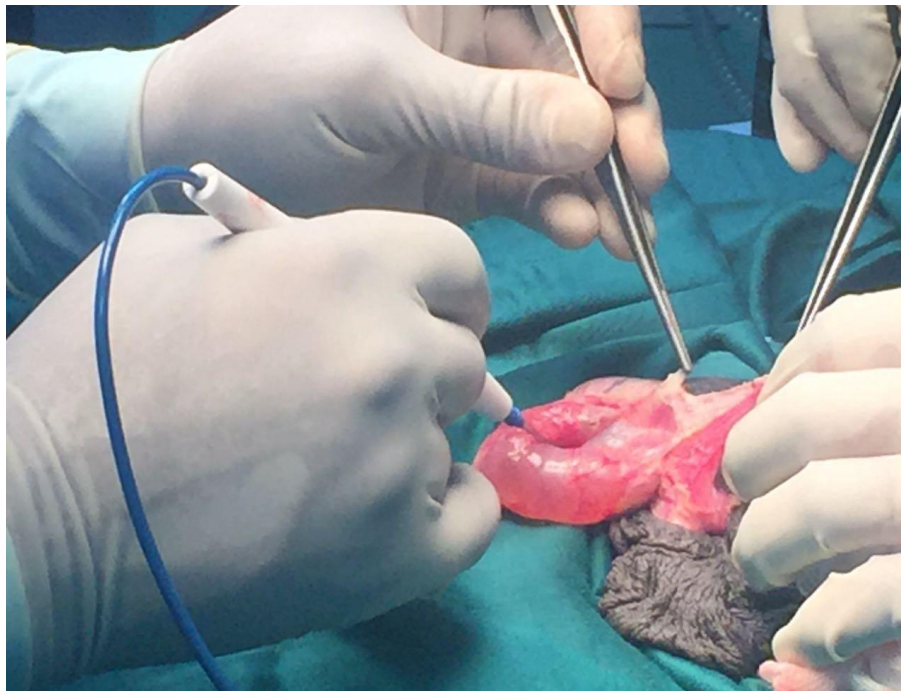
Following informed consent and spinal anesthesia, scrotal exploration was performed through median raphe incision. Intraoperatively, the sonographic findings were confirmed to be a result of supernumerary, normal sized indurated testis on the left (Figures 1 and 2), without spermatic chord or ductus deferens, a typed I according to Leung classification (Table 1). The right testis presents a voluminous epididymal cyst (Figure 3).




**Figure 1. Left Polyorchidism (Arrow): Normal in Size Supernumerary Testis but Indurated**



**Figure 2. Left Polyorchidism (Arrow): Normal in Size Supernumerary Testis, without vas and Spermatic Cord, Classified Type I According to Leung**



**Figure 3. Voluminous Right Epididymal Cyst (Arrow)**

**Table 1. Leung Anatomical Classification of Polyorchidism (Leung et al., 1998)****TYPES****I**

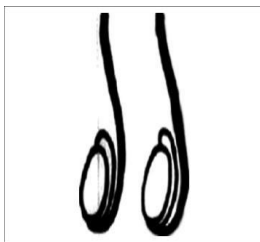
Supernumerary testis lacks an epididymis or vas and has got no attachment to the usual testis (Division of genital ridge only).

**II**

The supernumerary testis drains into epididymis of usual testis and they share a common vas. Division of genital ridge occurs in the region where the primordial gonads are attached to the metanephric ducts, although the mesonephros and metanephric ...

**III**

The supernumerary testis has its own epididymis and both epididymis of the ipsilateral testes draining into one vas. (Complete transverse division of mesonephros as well as genital ridge)

**IV**

Complete duplication of testes, epididymis and vas. (Vertical division of genital ridge and mesonephros)

We proceeded to a left orchietomy of the endured supernumerary testis, and an excision of the right epididymal cyst. The immediate postoperative period was uneventful, and the patient was discharged 12 hours following the surgery.

Subsequent histopathology identified normal testicular tissue with several tubules different in shapes and size but without atypia.

### 3. Discussion

Polyorchidism seems to be a rare urogenital anomaly with approximately 150 histologically confirmed cases reported in the literature. About 50% of these cases are detected between 15 and 25 years of age. But this pathology may be under-diagnosed, because usually asymptomatic (Bergholz et al., 2002).

In a normal embryo, at about 6 weeks of gestational age, the primordial testis develops from the primitive genital ridge medial to the mesonephric ducts. At about 8 weeks, the primordial testis takes shape, and the epididymis and vas deferens arise from the mesonephric (wolffian) duct. The exact mechanism for occurrence of polyorchidism is not known, but longitudinal or transverse division of the genital ridge, possibly by development of peritoneal bands, has been proposed. Its embryological etiology remains unconfirmed, but has been attributed to division of the genital ridge prior to the eight-week of development. However a few theories have been suggested including anomalous appropriation of cells in the genital ridge before 8 weeks of gestation, duplication or transverse vs longitudinal divisional of the urogenital ridge, incomplete degeneration of mesonephrons and development of peritoneal bands (Ozturk et al., 2006). The most common presentation for polyorchidism encountered is triorchidism with a hypotrophic supernumerary testis confined to the left side (Spranger et al., 2002).

Theories were partly verified in our case:

- The supernumerary testis was not hypotrophic but normal size.
- Our patient was older when diagnosed and father of four.
- The only correlating event was the left location of the testicle.

Often the supernumerary testis appears like a scrotal mass, which can be mistaken for a testicular or para-testicular tumor as it happened in our case. But the ultrasound showed an echo structure similar to the ipsilateral testis.

Color Doppler ultrasonography combined with Magnetic Resonance Imaging can help for a more accurate diagnosis (Bahloul et al., 2011).

The majority of polyorchidism cases are often identified randomly, while researching for the causes of other symptoms as inguinal hernia (30%), scrotal pain, testicular torsion (13%), maldescended testis (15-30%), hydrocele (9%), varicocele (<1%), anomalous urogenital union (<1%), malignancy (<1%); or incidentally determined during surgical exploration (Bergholz et al., 2009).

Opinions about management are controversial. Authors supporting the conservative approach argue that infertility is common finding in patients with polyorchidism and preserving a potential functional supernumerary testis to improve the capacity of spermatogenesis. It is suggested that the gonadal tissue should be left in the scrotum to maximize potential fertility (Ozturk et al., 2006; Teklali et al., 2007; Lawrentschuk et al., 2004).

Others argue that the majority of accessory testes have histologically reduced or absent spermatogenesis and propose that the increased risk of malignancy warrants removal of the supernumerary testis, particularly if it is non-viable, undescended or ectopically located.

In our case, we proceeded to an orchiectomy so far the supernumerary testicle macroscopically appeared

malignant and was endured when palpating, furthermore the patient did not manifest the need of future fatherhood. A regular clinical and ultrasonographic control would be performed during the patient follow-up, to exclude a malignant degenerating ipsilateral testis.

#### 4. Conclusion

Polyorchidism is a rare genitourinary abnormality and its management is still controversial. The management of polyorchidism will depend upon the location, size and anatomical organization of the testicular drainage system and the age of the patient.

Triorchidism is the most frequent manifestation, sole or associated with migration abnormality of the testicle. Standard ultrasound or coupled with color Doppler may confirm the diagnosis, MRI may provide additional information in complicated cases. Polyorchidism remains a therapeutic challenge related to fertility, malignancy risk and testicular torsion. The pathology exists and must be known by clinicians.

#### References

- Ashfeld F. (1880). *Die Missbildungen des Menschen*. Leipzig, Germany: Grunow.
- Bahloul, A. S., Nabolsi, T., Hassen, A., Bahloul, M., & Mhiri, N. (2011). Polyorchidism: A case report and review of the literature (in French). *Andrology*, *21*, 99-101.
- Bergholz, R., & Wenke, K. (2002). Polyorchidism: A meta-analysis. *J Urol.*, *182*(5), 2422-2427. <https://doi.org/10.1016/j.juro.2009.07.063>
- Lawrentschuk, N. et al. (2004). Polyorchidism: A case report and review of the literature. *Aust NZ J Surg.*, *74*(12), 1130-1132. <https://doi.org/10.1111/j.1445-1433.2004.03250.x>
- Leung, A. K. (1998). Polyorchidism. *Am Fam Physician*, *38*, 153-156.
- Ozturk, E. et al. (2006). Polyorchidism: Report of a case and review of the literature. *Eur J Radiol Extra*, *58*, 93-95. <https://doi.org/10.1016/j.ejrex.2006.03.004>
- Sarr, A. et al. (2015). Polyorchidie: A propos d'une nouvelle observation au Senegal. *Rev. M ál. Madag.*, *5*(2), 597-599.
- Spranger, R. et al. (2002). Polyorchidism: A strange anomaly with unsuspected properties. *J Urol.*, *168*(1), 198. [https://doi.org/10.1016/S0022-5347\(05\)64868-9](https://doi.org/10.1016/S0022-5347(05)64868-9)
- Teklali, Y. et al. (2007). Polyorchidie chez l'enfant à propos d'un cas avec revue de la littérature. *Prog Urol.*, *17*, 872-874. [https://doi.org/10.1016/S1166-7087\(07\)92312-X](https://doi.org/10.1016/S1166-7087(07)92312-X)