

Case Report

Tubulointerstitial Nephritis and Uveitis Syndrome—A Case Report and Review of Literature

Hamzeh Mohammad Alrawashdeh^{1*}, Yazan Abu Gharbieh¹, Omar Khalil Hamdan² & Mohammed Farah³

¹ Ophthalmology Department, Ibn Alhaytham Hospital, Amman, Jordan

² Pathology Department, Jordan University Hospital, Amman, Jordan

³ Shami Eye Center, Amman, Jordan

* Hamzeh Mohammad Alrawashdeh, Ophthalmology Department, Ibn AL Haytham Hospital, Amman, PO Box 940614, 11194 Amman, Jordan

Received: January 8, 2020

Accepted: January 12, 2020

Online Published: January 16, 2020

doi:10.22158/rhs.v5n1p27

URL: <http://dx.doi.org/10.22158/rhs.v5n1p27>

Abstract

A very little subset of patients diagnosed with interstitial nephritis have the tubulointerstitial nephritis and uveitis (TINU syndrome). A considerable number of cases have been documented in the pediatric nephrology and ophthalmology literature. We report a 12-year-old girl who presented with a history of allergic/drug-induced tubulointerstitial nephritis and diagnosed months later to have uveitis after stopping steroids. This considered a very rare combination and the diagnosis of tubulointerstitial nephritis and uveitis syndrome was established. She was treated successfully with topical steroid and topical cycloplegic agent for about 7 weeks. About 250 cases have been reported worldwide, and this is the first reported case in Jordan.

Keywords

tubulointerstitial nephritis, uveitis, tubulointerstitial nephritis and uveitis syndrome, nephropathy, kidney biopsy

1. Introduction

Tubulointerstitial nephritis (TIN) is a primary injury of both renal tubules and interstitium leading to a decrease in renal function. The acute form is more common. More than 95% of cases result from infection or an allergic drug reaction.

Tubulointerstitial Nephritis and Uveitis Syndrome depicts a rare form of non-granulomatous bilateral anterior uveitis found in a subgroup of patients affected with tubulointerstitial nephritis. It may precede,

follow or develop simultaneously with uveitis. It was first described by Dobrin et al. (1975), Grefer and Dusek et al. (1985) gave the name tubulointerstitial nephritis and uveitis syndrome (TINU) (Grefer et al., 1999). More than 250 cases have been reported until now (Abed, Merouani, Haddad, Benoit, Oligny, & Sartelet, 2008; Li, Su, Chu, Li, & Yang, 2014). Altogether, more than 100 cases have been reported in Japan in which TINU syndrome is considered the second most frequent diagnosis in children with uveitis after sarcoidosis (Goda, Kotake, Ichiishi, Namba, Kitaichi, & Ohno, 2005). The uveitis is generally mild and the nephritis self-limited. However, cases of chronic uveitis and renal failure have been reported.

2. Case Presentation

A 12-year-old female patient, not known to have any medical problems presented to the emergency department with a history of decreased oral intake, nausea, urgency, suprapubic pain, malodorous urine and dysuria for one week. Her labs revealed normal CBC, elevated CRP (41.8 mg/L), turbidity in urine with high WBCs (550), RBCs (100), +1 protein, +1 glucose, with the presence of bacteria, nitrite, and epithelial cells. She was managed as a case of acute bacterial cystitis started on intravenous fluids, antiemetic (Ondansetron 0.15 mg/kg) and 1g ceftriaxone in the ER for 2 days followed by once a day oral cefixime (8 mg/kg/day) for another 5 days as urine culture revealed bacterial growth.

Six weeks later, she presented again to the ER, complaining of decreased activity, fatigue, malaise, anorexia, weight loss (about 4 kg in 6 weeks) along with episodes of nausea, vomiting, flank pain, oliguria, skin rash and low-grade fever for 5 days. Her labs showed Hb of (8.6 g/dl), WBCs ($6.37 \times 10^9/L$), eosinophilia (> 5%), ASO titer (500), creatinine (2.78 mg/dl), urea (25 mg/dl), serum phosphorus (3.95 mg/dl), serum bicarbonate (15.4 mg/dl), vitamin D (7 ng/ml), urine analysis revealed +1 protein with +1 glucose, and a negative urine culture after 3 days. Abdominal ultrasound showed enlargement of both kidneys (10.5-10.8 cm) with increased parenchymal thickness and echogenicity with no signs for obstructive uropathy, hence she was admitted to the hospital by her pediatrician.

After the stabilization of her condition, she underwent a kidney biopsy which revealed diffuse interstitial nephritis with infiltration of eosinophil, macrophages, lymphocytes and plasma cells without evidence of granuloma, also the immunofluorescent evaluation of the biopsy was negative for IgG, IgM, IgA, C3, C4, C1q and fibrin. She was diagnosed with acute tubulointerstitial nephritis and received three intravenous doses of 500 mg methylprednisolone over one hour once daily for three days. After 5 days, she was discharged on 1 mg/kg/day (40 mg) of oral prednisolone, famotidine 20 mg/day, calcium 500 mg/day, iron syrup (0.48 mg/kg/day), vitamin D 500 IU/day, and one-alpha 0.25 mic/day. After 1 month as her kidney function recovered, the dose was tapered to 5 mg weekly over the next 2 months.

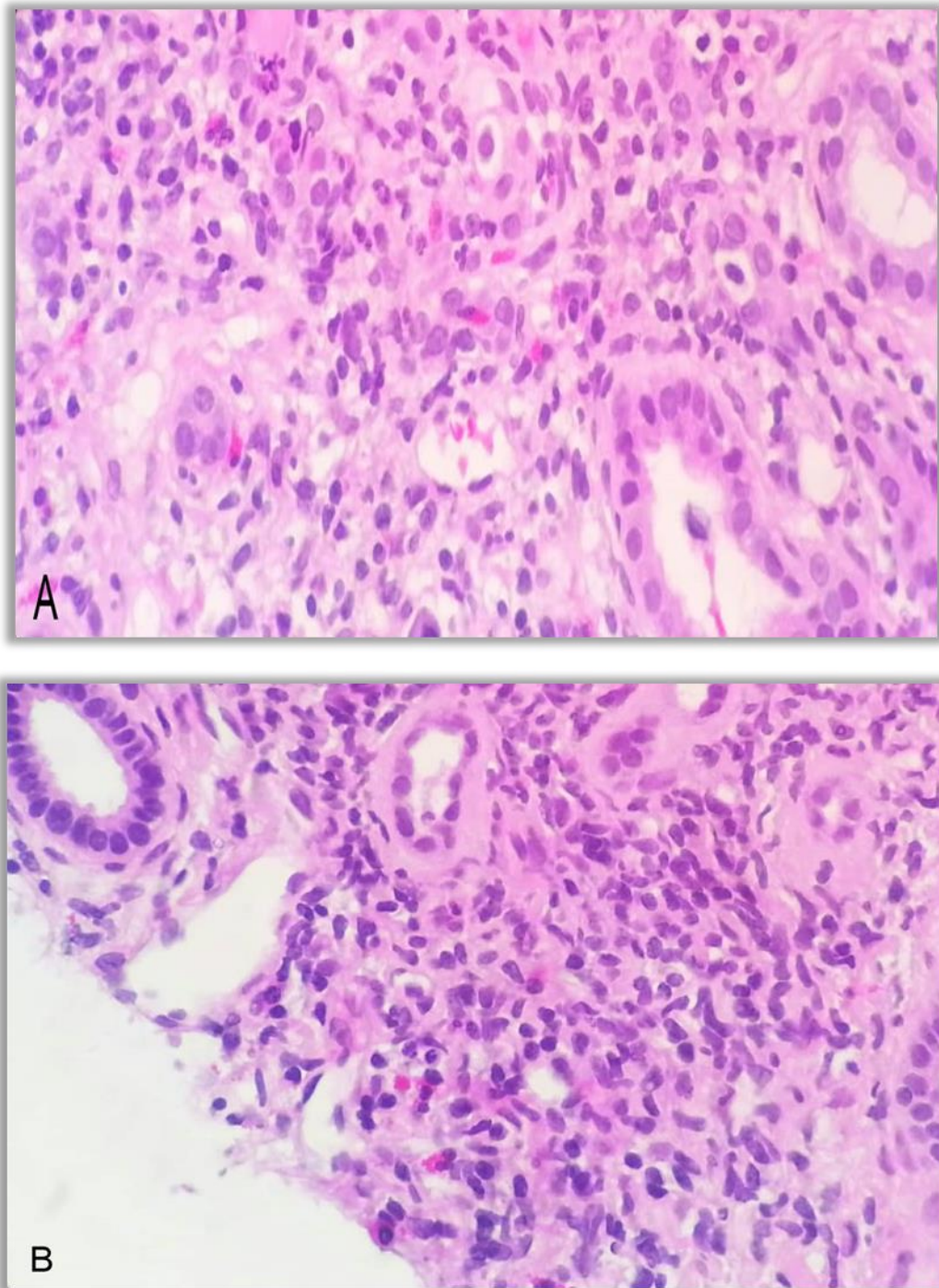


Figure 1. A and B: Renal Biopsy for the Patient Reveals Acute Allergic/ Drug-induced Tubulointerstitial Nephritis and Contains Normal Glomeruli

The interstitium shows generalized edema with minimal fibrosis and dense infiltration by lymphocytes, plasma cells, macrophages, and eosinophils. The tubules show epithelial damage and luminal white blood cells. The blood vessels are normal.

The patient presented to our ophthalmology clinic with bilateral epiphora, photophobia, and eye redness. She was complaining of red-eye the week before, accordingly, she was diagnosed to have viral conjunctivitis and treated with lubricating eye drops by a general practitioner.

Upon examination, the best-corrected visual acuity was 20/40 for her right and left eyes. Slit-lamp examination showed severe limbal injection bilaterally with corneal edema, +4 anterior chamber cells, flare, fine diffuse endothelial precipitates, and severe inflammatory membrane clumped to both irides with posterior synechia.

Further detailed questioning led us to the history of kidney insult about 4 months ago and apparently, her eye symptoms started 2 weeks after stopping oral steroids. To exclude the other systemic diseases that can cause uveitis such as sarcoidosis Sjögren's syndrome, systemic lupus erythematosus, Behçet's syndrome, Wegener's granulomatosis, immunoglobulin G4 (IgG4)-related autoimmune disease, and infectious diseases, further testing were performed ANA, c-ANCA, p-ANCA, Anti-ds DNA, Anti Ro, Anti La, QuantiFERON-TB Gold test (QFT-G), IgG4 serum level, angiotensin-converting enzyme level, infectious diseases serological tests and chest X-ray all were negative or within normal limits.

The patient was started on topical corticosteroids every two hours and topical cycloplegic eye drops three times a day then referred to her nephrologist to reassess. One week later the anterior chamber reaction dropped to +2 cells, the inflammatory membrane had nearly disappeared and the fundus exam was normal. After two weeks her eyes were quiet, her best-corrected vision was 20/20 for both eyes, and her labs were within normal limits. The topical cycloplegic agent was stopped and the topical corticosteroid was tapered over the next 4 weeks.

The diagnosis of tubulointerstitial nephritis and uveitis (TINU) syndrome was established and she was followed up regularly.

3. Discussion

Tubulointerstitial Nephritis and Uveitis (TINU) syndrome is a rare oculorenal inflammatory disease accounting for less than 1-2% of all patients presenting to ophthalmology (Mackensen & Billing, 2009). The true prevalence is unknown exactly and supposedly be higher because undiagnosed cases are considered idiopathic. On average, TINU occurs in approximately 65% of patients with TIN (Mandeville, Levinson, & Holland, 2001) in whom renal tubular defects are found usually. The mean age of presentation is 15 years with female to male ratio 3:1 (Mandeville, Levinson, & Holland, 2001). There is an increased proportion of affected males in recent reports (Sinnamon, Courtney, & Harron, 2008) with a trend towards a male predominance in younger age groups (Yoshioka, Takemura, Kanasaki, Akano, & Maki, 1991). There is no association with particular racial or ethnic groups, or geographical distribution (Mandeville, Levinson, & Holland, 2001; Mackensen et al., 2011).

The cause of TINU is unknown but various associations had revealed in researches. Certain HLA genotypes (including HLA-DQA1 and DRB1) increase the relative risk of developing TINU in certain populations (Yoshioka, Takemura, Kanasaki, Akano, & Maki, 1991; Mackensen et al., 2011). In addition,

medications have been implicated as antibiotics or NSAIDs. The drug causing hapten-induced cytokine production or hypersensitivity and immune reaction. Another possibility correlated to dysfunction or targeted disruption of similar enzymes in the renal tubule and ciliary epithelium.

The underlying mechanisms for TINU are not fully recognized yet. Limited data suggest that modified C-reactive protein (mCRP), an autoantigen common to both the uvea and renal tubular cells, may play a role in the pathogenesis (Tan et al., 2011). In a study of 97 patients with various renal disorders and 40 healthy controls, the prevalence of immunoglobulin G (IgG) antibodies directed against CRP was significantly higher among nine patients with TINU syndrome (100%) than among those with Sjögren's associated interstitial nephritis (29%), drug-induced interstitial nephritis (36%), glomerulonephritis (5%), and healthy controls (0 percent) (Tan et al., 2011). Another study by the same group proved that patients with TINU syndrome and late-onset uveitis had a higher level of mCRP compared with those with drug-induced interstitial nephritis (Li, Su, Chu, Li, & Yang, 2014).

The inflammation in TINU syndrome is thought to be induced by T-lymphocyte mainly, based upon the histology. In contrast, immune cells in patients with TINU syndrome have a paradoxical suppression of cytokine production and a decrease in the peripheral immune response. This paradox is not unique to TINU, as the presence of increased tissue inflammation with concomitant suppression of peripheral immunity is also seen in patients with sarcoidosis (Gafer et al., 1993; Levinson et al., 2003).

No identifiable risk factors are known at least in 50 percent of cases. In some patients, prior infection or the use of specific drugs (antibiotics and nonsteroidal anti-inflammatory drugs (NSAIDs)) has been implicated (Li, Su, Chu, Li, & Yang, 2014; Mandeville, Levinson, & Holland, 2001). The Chinese herb, "Goreisan", was reported as a trigger (Suzuki et al., 2009). Concurrent Chlamydia and Epstein-Barr virus infections have been described (Grefer et al., 1999; Stupp, Mihatsch, Matter, & Streuli, 1990). TINU syndrome has also been reported in patients with autoimmune diseases like hypothyroidism, hypoparathyroidism, rheumatoid arthritis, and immunoglobulin G4 (IgG4)-related diseases (Catalano et al., 1989).

Patients usually present with typical anterior uveitis symptoms like (eye pain, redness, and photophobia). Symptoms of TIN are not always clear and include malaise, fever, fatigue, and loin pain or tenderness. The general malaise usually precedes the ocular findings. The ocular symptoms can precede (21%) by up to two months (Yoshioka, Takemura, Kanasaki, Akano, & Maki, 1991), occur concurrently (15%) or follow TIN (65%).

More than 80% of cases with bilateral acute, anterior, non-granulomatous uveitis, however, few cases of posterior uveitis and panuveitis were reported (Mackensen & Billing, 2009; Mandeville, Levinson, & Holland, 2001). In 2006 a case of nodular scleritis preceding TINU syndrome in adults was reported indicating that episcleritis may be part of the ocular inflammation occurring in TINU syndrome (Daniel, Gangaputra, Kempen, & Jabs, 2006). In 2001 Mandeville et al have published the evaluation criteria for the TINU syndrome (Mandeville, Levinson, & Holland, 2001) depend on the presence of acute interstitial nephritis and uveitis, without any underlying disease, in addition to the following: abnormal

kidney function test, abnormal urinalysis, and Systemic disease duration of at least 2 weeks.

The differential diagnosis of TINU is a crucial issue to know, as it is important to exclude any systemic causes. This list of differential may include sarcoidosis, Behcet's disease, systemic lupus erythematosus Wegener's granulomatosis, Sjogren's syndrome primary hyperparathyroidism, hyperthyroidism, and infectious causes. A reliable diagnosis can be made from proper ophthalmic exam and laboratory evaluation. However, a definitive diagnosis can only be established with renal biopsy (Helms, Servilla, Hartshorne, Harris, Nichols, & Tzamaloukas, 2005). In addition, beta-2 microglobulin, eosinophils, proteinuria, hematuria, pyuria, white cells casts, and normoglycemic glucosuria may be detected. The ANCA, anticardiolipin antibodies, anti-DNA antibody, antinuclear antibody, and rheumatoid factor could be positive in addition to hypocomplementemia, polyclonal hypergammaglobulinemia and circulating immune complexes (Goda, Kotake, Ichiishi, Namba, Kitaichi, & Ohno, 2005; Mandeville, Levinson, & Holland, 2001; Paladini, Venturoli, Mosconi, Zambianchi, Serra, & Valletta, 2013).

Although TIN may resolve spontaneously, the corticosteroid is the treatment of choice for patients with progressive renal failure. About 11% of nephropathy cases become chronic and no more than 5% of patients require dialysis (Hinkle & Foster, 2008). The using of topical steroids with cycloplegic agents is recommended for anterior uveitis (Parameswaran et al., 2010; Gion, Stavrou, & Foster, 2000). Some refractory cases need oral steroids (Gion, Stavrou, & Foster, 2000; Thomassen, Ring, Thaarup, & Baggesen, 2009) or rarely, immunosuppressive agents (Gion, Stavrou, & Foster, 2000; Thomassen, Ring, Thaarup, & Baggesen, 2009; Liakopoulos et al., 2006). In 14% of the cases, the symptoms of uveitis persist for more than 12 weeks (Liakopoulos et al., 2006) with 50% of recurrence (Yoshioka, Takemura, Kanasaki, Akano, & Maki, 1991).

In our case, the main cause of TIN was allergic/drug-induced, which is thought to be the etiology for 60-70% of cases (Nat Rev Nephrol., 2010). Multiple drugs from different classes may induce TIN. Antibiotics such as cephalosporins, penicillins, sulfonamides, rifampin, and ciprofloxacin accounting for about 25% of cases (Praga & Gonzalez, 2010). The cephalosporins were implicated in this case. The patient responded well to systemic corticosteroids and her eyes showed improvement with the treatment.

4. Conclusion

Tubulointerstitial nephritis and Uveitis Syndrome is a rare entity that is usually underestimated due to the unique presentation, therefore, ophthalmologists should recognize and consider it if the clinical history is suspicious. Any patient presented with uveitis and history of tubulointerstitial nephritis, especially adolescents, should be investigated and evaluated before establishing the diagnosis of TINU syndrome, because uveitis may be due to another unremarkable disease and not related to the tubulointerstitial nephritis.

References

- Abed, L., Merouani, A., Haddad, E., Benoit, G., Oligny, L. L., & Sartelet, H. (2008). Presence of autoantibodies against tubular and uveal cells in a patient with tubulointerstitial nephritis and uveitis (TINU) syndrome. *Nephrol Dial Transplant*, *23*. <https://doi.org/10.1093/ndt/gfm890>
- Birnbaum et al. (2012). *Arch Ophthalmol.*, *130*(11), 1389-1394. <https://doi.org/10.1001/archophthalmol.2012.2006>
- Catalano, C. et al. (1989). Acute interstitial nephritis associated with uveitis and primary hypoparathyroidism. *Am J Kidney Dis.*, *14*, 317. [https://doi.org/10.1016/S0272-6386\(89\)80212-4](https://doi.org/10.1016/S0272-6386(89)80212-4)
- Daniel, E., Gangaputra, S., Kempen, J. H., & Jabs, D. A. (2006). Recurrent nodular scleritis preceding an adult TINU syndrome. *Ocul Immunol Inflamm.*, *14*, 239-240. <https://doi.org/10.1080/09273940600826612>
- Dobrin, R. S., Vernier, R. L., & Fish, A. L. (1975). Acute eosinophilic interstitial nephritis and renal failure with bone marrow-lymph node granulomas and anterior uveitis: A new syndrome. *Am J Med.*, *59*, 325-333. [https://doi.org/10.1016/0002-9343\(75\)90390-3](https://doi.org/10.1016/0002-9343(75)90390-3)
- Gafter, U., Kalechman, Y., Zevin, D., Korzets, A., Livni, E., Klein, T., ... Levi, J. (1993). Tubulointerstitial nephritis and uveitis: Association with suppressed cellular immunity. *Nephrol Dial Transplant*, *8*(9), 821.
- Gion, N., Stavrou, P., & Foster, C. S. (2000). Immunomodulatory therapy for chronic tubulointerstitial nephritis-associated uveitis. *Am J Ophthalmol.*, *129*, 764-768. [https://doi.org/10.1016/S0002-9394\(00\)00482-7](https://doi.org/10.1016/S0002-9394(00)00482-7)
- Goda, C., Kotake, S., Ichiishi, A., Namba, K., Kitaichi, N., & Ohno, S. (2005). Clinical features in tubulointerstitial nephritis and uveitis (TINU) syndrome. *Am J Ophthalmol.*, *140*, 637-641. <https://doi.org/10.1016/j.ajo.2005.04.019>
- Grefer, J. et al. (1999). Tubulointerstitial nephritis and uveitis in association with Epstein-Barr virus infection. *Pediatr Nephrol.*, *13*, 336. <https://doi.org/10.1007/s004670050621>
- Helms, E., Servilla, K. S., Hartshorne, M. F., Harris, A., Nichols, M. J., & Tzamaloukas, A. H. (2005). Tubulointerstitial nephritis and uveitis syndrome: Use of gallium scintigraphy in its diagnosis and treatment. *Int Urol Nephrol.*, *37*, 119-122. <https://doi.org/10.1007/s11255-004-2356-1>
- Hinkle, D. M., & Foster, C. S. (2008). Tubulointerstitial nephritis and uveitis syndrome. *Int Ophthalmol Clin.*, *48*, 9-13. <https://doi.org/10.1097/IIO.0b013e3181694db9>
- Levinson, R. D. et al. (2003). Strong associations between specific HLA-DQ and HLA-DR alleles and the tubulointerstitial nephritis and uveitis syndrome. *Invest Ophthalmol Vis Sci.*, *44*, 653-657. <https://doi.org/10.1167/iovs.02-0376>
- Li, C., Su, T., Chu, R., Li, X., & Yang, L. (2014). Tubulointerstitial nephritis with uveitis in Chinese adults. *Clin J Am Soc Nephrol.*, *9*(1), 21. <https://doi.org/10.2215/CJN.02540313>
- Liakopoulos, V. et al. (2006). Tubulointerstitial nephritis and uveitis (TINU) syndrome in a 52-year-old female: A case report and review of the literature. *Ren Fail.*, *28*, 355-359.

- <https://doi.org/10.1080/08860220600577775>
- Mackensen et al. (2011). *Br J Ophthalmol.*, 95, 971-976.
- Mackensen, F., & Billing, H. (2009). Tubulointerstitial nephritis and uveitis syndrome. *Curr Opin Ophthalmol.*, 20, 525-318. <https://doi.org/10.1097/ICU.0b013e3283318f9a>
- Mandeville, J. T. H., Levinson, R. D., & Holland, G. N. (2001). The Tubulointerstitial Nephritis and Uveitis Syndrome. *Surv Ophthalmol.*, 46, 195-208. [https://doi.org/10.1016/S0039-6257\(01\)00261-2](https://doi.org/10.1016/S0039-6257(01)00261-2)
- Matsumoto, Keiichiro; Fukunari, Kenichi; Ikeda, Yuji; Miyazono, Motoaki; Kishi, Tomoya; Matsumoto, Ryoko; Fukuda, Makoto; Uchiumi, Saori; Yoshizaki, Mai. (2015, January 1). *Nat Rev Nephrol.*, 6(8), 461-470.
- Paladini, A., Venturoli, V., Mosconi, G., Zambianchi, L., Serra, L., & Valletta, E. (2013). Tubulointerstitial nephritis and uveitis syndrome in a twelve-year-old girl. *Case Rep Pediatr.*, 652043. <https://doi.org/10.1155/2013/652043>
- Parameswaran, S. et al. (2010). Tubulointerstitial nephritis with uveitis syndrome: A case report and review of literature. *Indian J Nephrol.*, 20, 103-105. <https://doi.org/10.4103/0971-4065.65307>
- Praga, M., & Gonzalez, E. (2010). Acute interstitial nephritis. *Kidney Int.*, 77(11), 956-961. <https://doi.org/10.1038/ki.2010.89>
- Sinnamon, K. T., Courtney, A. E., & Harron, C. (2008). Tubulointerstitial nephritis and uveitis (TINU) syndrome: Epidemiology, diagnosis and management. *Nephrol Dial Transplant Plus.*, 2, 112-116. <https://doi.org/10.1093/ndtplus/sfn006>
- Stupp, R., Mihatsch, M. J., Matter, L., & Streuli, R. A. (1990). Acute tubulo-interstitial nephritis with uveitis (TINU syndrome) in a patient with serologic evidence for Chlamydia infection. *Klin Wochenschr.*, 68, 971. <https://doi.org/10.1007/BF01646656>
- Suzuki, H. et al. (2009). Tubulointerstitial nephritis and uveitis (TINU) syndrome caused by the Chinese herb "Goreisan". *Clin Exp Nephrol.*, 13, 73. <https://doi.org/10.1007/s10157-008-0069-y>
- Tan, Y., Yu, F., Qu, Z., Su, T., Xing, G. Q., Wu, L. H., ... Zhao, M. H. (2011). Modified C-reactive protein might be a target autoantigen of TINU syndrome. *Clin J Am Soc Nephrol.*, 6(1), 93. <https://doi.org/10.2215/CJN.09051209>
- Thomassen, V. H., Ring, T., Thaarup, J., & Baggesen, K. (2009). Tubulointerstitial nephritis and uveitis (TINU) syndrome: A case report and review of the literature. *Acta Ophthalmol.*, 87, 676-679. <https://doi.org/10.1111/j.1755-3768.2008.01302.x>
- Yoshioka, K., Takemura, T., Kanasaki, M., Akano, N., & Maki, S. (1991). Acute interstitial nephritis and uveitis syndrome: Activated immune cell infiltration in the kidney. *Pediatr Nephrol.*, 5(2), 232. <https://doi.org/10.1007/BF01095961>