

Case Report

A Challenging Case of Adrenal Insufficiency Presenting with Hypertensive Crisis

Ahmad Al-Abdouh^{1*}, Ghazal Kooshk Jalali¹ & Sanaz Sakiani²

¹ Department of Medicine, Saint Agnes Hospital, Baltimore, MD, United States of America

² Department of Endocrinology, Saint Agnes Hospital, Baltimore, MD, United States of America

* Ahmad Al-Abdouh, Department of Medicine, Saint Agnes Hospital, Baltimore, MD, 21229, United States of America

Received: January 20, 2020

Accepted: January 27, 2020

Online Published: February 5, 2020

doi:10.22158/rhs.v5n1p35

URL: <http://dx.doi.org/10.22158/rhs.v5n1p35>

Abstract

Adrenal insufficiency is the deficient production or action of glucocorticoids, with or without deficiency in mineralocorticoids or adrenal androgens. It usually presents with anorexia, abdominal pain, weakness, weight loss, fatigue, and hypotension. We report a case of 67 year old male, who is known to have hypertension, presented to emergency room with severe headache and was found to have high blood pressure 241/135mmHg and hyposmolar hyponatremia. He was started on intravenous nicardipine and his blood pressure dropped suddenly, became orthostatic, and required fluid resuscitation but his headache resolved. On next day, the cosyntropin test was suggestive of primary adrenal insufficiency. The patient was started on oral hydrocortisone with improvement in his blood pressure and hyponatremia.

Keywords

Addison, adrenal insufficiency, Hypertension, crisis

1. Introduction

Hypertension is a common chronic medical condition (Oparil et al., 2018) and when uncontrolled, it can progress to a hypertensive crisis defined as a systolic blood pressure >180 mmHg or a diastolic blood pressure >120 mmHg. Hypertensive crisis can be further classified as a hypertensive urgency or hypertensive emergency depending on end-organ involvement including cardiac, renal, and neurologic injury (Rodriguez, Kumar, & De Caro, 2010).

Adrenal insufficiency is the deficient production or action of glucocorticoids, with or without deficiency in mineralocorticoids or adrenal androgens. The clinical manifestations usually include anorexia,

abdominal pain, weakness, weight loss, fatigue, hypotension, and hyperpigmentation of the skin in case of primary adrenal insufficiency (Charmandari, Nicolaidis, & Chrousos, 2014; Nicolaidis, Chrousos, & Charmandari, 2000). Therefore, hypertensive crisis is not considered to be an expected presentation.

We hereby present an unusual case of a patient who presented with severe headache in settings of hypertensive crisis and was found to have primary adrenal insufficiency.

2. Case Presentation

A 67 year old white male, known to have peripheral vascular disease, presented complaining of a headache that was associated with an increase in his blood pressure (210-240/110-120 mmHg at home) a few hours before presentation. His systolic blood pressure readings were usually 120-130 mmHg; however, during the 4-5 months before presentation, it had been fluctuating widely. The headache was bitemporal, throbbing in nature, intermittent, 10/10 in severity, and associated with dizziness and general weakness.

On examination, he was noted to have blood pressure of 241/135 mmHg, a left carotid bruit, and diffuse excoriations along the anterior shins but no edema or hyperpigmentation.

Laboratory tests showed sodium level 123 mmol/L (reference range 135–145 mmol/L), potassium 4.4 mmol/L (reference range 3.5-5.2 mmol/L), measured serum osmolality 262 mOsm/kg (275-295 mOsm/kg) urine osmolality 651 mOsm/kg (reference level 300-900 mOsm/kg), urine random sodium 216 meq/L and urine random creatinine 106.1 mg/dL. The calculated FENa was 1.2%. The morning cortisol level was 4.1 ug/dl (reference range 6.2-19.4 ug/dl), baseline adrenocorticotrophic hormone (ACTH) 81 pg/mL (reference range 7-69 pg/mL). A cosyntropin stimulation test was performed the next day and was suggestive of primary adrenal insufficiency (Figure 1). Secondary causes of hypertension were considered, such as renal artery stenosis, hypothyroidism, pheochromocytoma, and hyperaldosteronism. Plasma renin activity (PRA) was 0.2 ng/mL/h (reference range 0.2-1.6 ng/mL/h), 21-hydroxylase antibody was 0.2 (reference range <1.0 unit/mL), plasma metanephrine 0.11nmol/L (reference range 0.00-0.49 nmol/L), normetanephrine 0.46 (reference range 0.00-0.89 nmol/L), aldosterone level 8.1 ng/dL (reference range <16.0 ng/dL supine). Abdominal computed tomography (CT) scan showed a 9.0 mm, hypodense, left adrenal adenoma and brain CT scan was unremarkable. The patient was diagnosed as having a hypertensive crisis and was found to have Addison disease simultaneously. Acute treatment included intravenous nicardipine (2 mg/hour), due to the severely symptomatic nature of his hypertensive crisis despite the absence of other evidence of end-organ damage. About after 4 hours of being on the nicardipine drip, his blood pressure dropped suddenly to 103/57 mmHg, he became orthostatic and required fluid resuscitation, but his headache resolved. The following day he was started on oral hydrocortisone, after completion of the cosyntropin stimulation test, which led to improvement in his blood pressure and hyponatremia (Figure 2).

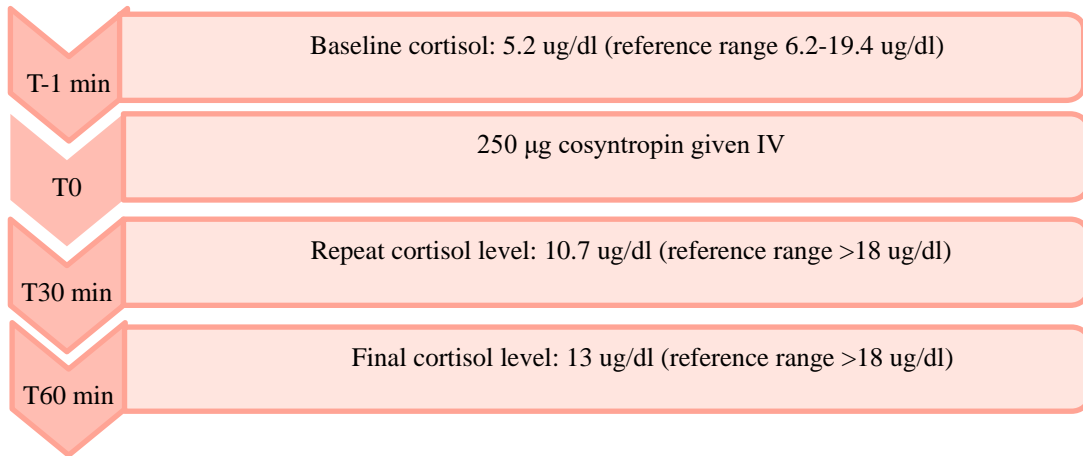


Figure 1. Cosyntropin Stimulation Test

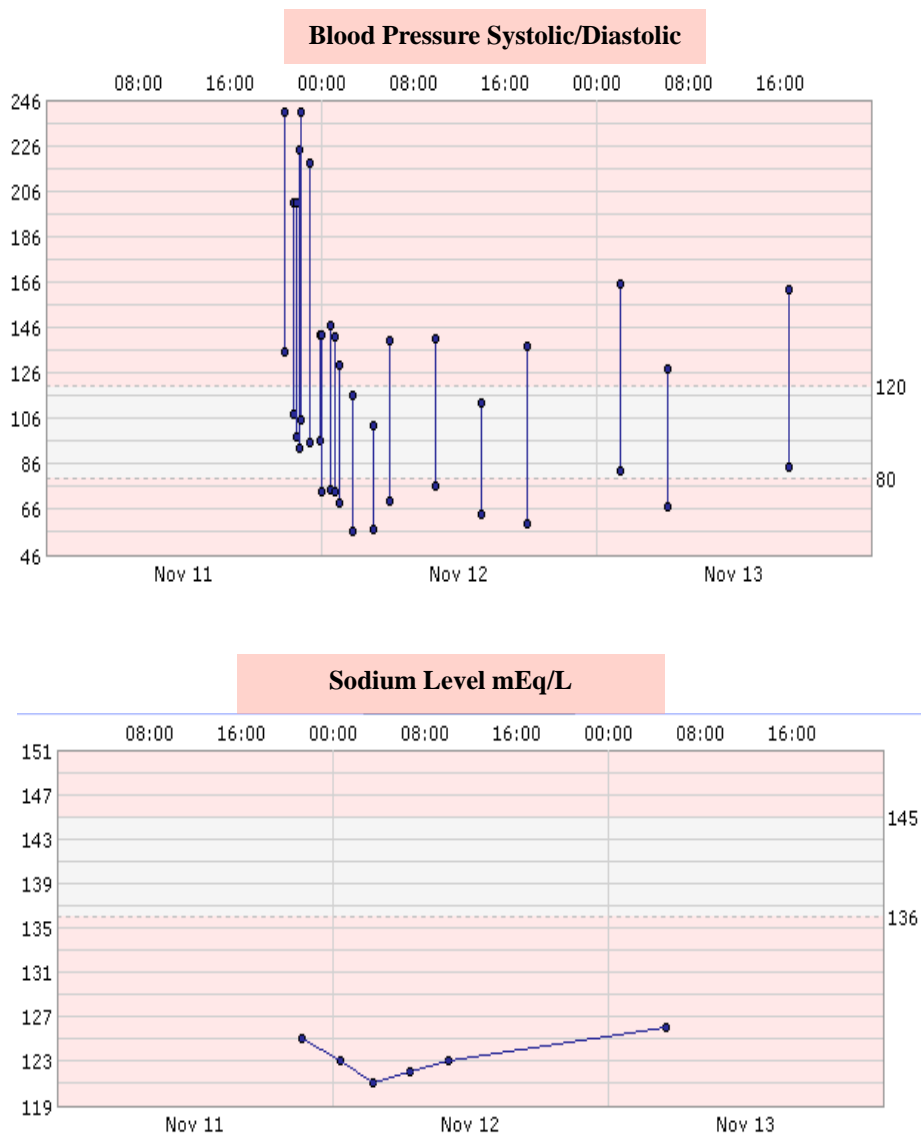


Figure 2. Blood Pressure and Sodium Level during Admission

3. Discussion

Hypertension is not known to be a common presentation of adrenal insufficiency, most patients usually have low blood pressure (Papierska & Rabijewski, 2013). While it is possible for hypertension to be present along with adrenal insufficiency in rare forms of congenital adrenal hyperplasia, such as 11 β hydroxylase deficiency (Chemaitilly, Wilson, & New, 2003; van Deijk, Blom, & VD Vijver, 1979) or 17 α hydroxylase deficiency (van Deijk, Blom, & VD Vijver, 1979), these are usually diagnosed in childhood. There is also Allgrove syndrome (3A syndrome) which is usually diagnosed in childhood, and consists of alacrima, achalasia, and adrenal insufficiency due to ACTH resistance. If autonomic dysfunction is also present, this is termed as 4A Syndrome (Aftab, Manzoor, Talat, Khan, Subhanie, & Khalid, 2016). We identified a few similar case reports of adults newly diagnosed with adrenal insufficiency (not taking corticosteroids) presenting with hypertension, only one was written in English in 1979 and the cause was thought to be partial 11 β hydroxylase deficiency.⁷ Our patient did not have any sign of end organ damage but he had a severe headache which prompted the decision to treat him with an intravenous antihypertensive drip. The treatment in these patients is particularly challenging since there is a need to have a balance between glucocorticoid replacement, while maintaining a normal blood pressure. We conclude that, though unexpected and rare, and provided that there is enough suspicion to make this diagnosis early in the presentation, hypertension should be treated cautiously in such patients to avoid significant and potentially deleterious drops in blood pressure. As a result, while there is no literature guidance available on the matter, we think that intravenous titratable antihypertensives can still be used in these patients but with more caution.

4. Conclusion

Hypertension is not an expected finding in patients with adrenal insufficiency. Our diagnosis of adrenal insufficiency was based on cosyntropin test which was associated with hypertensive crisis. Rapid acting, easily titratable anti-hypertensives administered intravenously at appropriate infusion rate are reasonable first line treatment for hypertensive crisis but should be used cautiously in patients with adrenal insufficiency.

References

- Aftab, S., Manzoor, J., Talat, N., Khan, H. S., Subhanie, M., & Khalid, N. A. (2016). Allgrove Syndrome: Adrenal Insufficiency with Hypertensive Encephalopathy. *J Coll Physicians Surg Pak.*, 26(9), 790-792.
- Charmandari, E., Nicolaides, N. C., & Chrousos, G. P. (2014). Adrenal insufficiency. *Lancet (London, England)*, 383(9935), 2152-2167. [https://doi.org/10.1016/S0140-6736\(13\)61684-0](https://doi.org/10.1016/S0140-6736(13)61684-0)
- Chemaitilly, W., Wilson, R. C., & New, M. I. (2003). Hypertension and adrenal disorders. *Curr Hypertens Rep.*, 5(6), 498-504. <https://doi.org/10.1007/s11906-003-0058-1>

- Nicolaidis, N. C., Chrousos, G. P., & Charmandari, E. (2000). Adrenal Insufficiency. In K. R. Feingold, B. Anawalt, & A. Boyce et al. (Eds.), *South Dartmouth (MA)*.
- Oparil, S. et al. (2018). Hypertension. *Nat Rev Dis Prim.*, 4, 18014. <https://doi.org/10.1038/nrdp.2018.14>
- Papierska, L., & Rabijewski, M. (2013). Delay in diagnosis of adrenal insufficiency is a frequent cause of adrenal crisis. *Int J Endocrinol*, 482370. <https://doi.org/10.1155/2013/482370>
- Rodriguez, M. A., Kumar, S. K., & De Caro, M. (2010). Hypertensive crisis. *Cardiol Rev.*, 18(2), 102-107. <https://doi.org/10.1097/CRD.0b013e3181c307b7>
- van Deijk, W. A., Blom, P. S., & VD Vijver, J. C. (1979). Primary adrenal insufficiency with hypertension. A case report on partial primary adrenal insufficiency and partial 11-beta-hydroxylase deficiency. *Neth J Med.*, 22(6), 191-194.